

ROLE OF DUAL-SOURCE MULTIDETECTOR COMPUTED TOMOGRAPHY IN ASSESSMENT OF LEFT VENTRICULAR GLOBAL AND REGIONAL FUNCTION IN COMPARISON TO ECHOCARDIOGRAPHY

Nader T Kandil,*; Hisham S Roshdy,*; Montaser M Al-Cekelly,*; Ahmed S Al-Saeid,**

*Cardiology Department, Faculty of Medicine, Zagazig University, Zagazig, Egypt.

**Radiology Department, National Heart Institute, Cairo, Egypt.

ABSTRACT

Aims: Multidetector computed tomography (MDCT) is used largely to evaluate the coronary arteries. Currently, MDCT is being considered for the assessment of the left ventricular function. The aim of this study is to evaluate the diagnostic accuracy of MDCT in assessment of global and regional left ventricular (LV) function in comparison to echocardiography.

Methods: Sixty four-slice multidetector computed tomography studies evaluating the global LV function and regional wall motion abnormalities (RWMA) of 30 consecutive patients were compared to their echocardiographic estimated LV ejection fraction and RWMA.

Results: Global LV function evaluation demonstrated a highly significant strong positive correlation ($r = 0.966$, $p < 0.0001$) between both techniques, Bland–Altman analysis showed good agreement between both modalities with mean difference of $-1.8\% \pm 2.5\%$ (mean \pm 2STD). For RWMA evaluation good agreement was shown between the two techniques, with 95.9% (489 of 510 segments) of the segments scored identically with use of both modalities. Agreement with the individual grading for the regional wall motion (normokinesia, hypokinesia, akinesia and dyskinesia) were 96%, 94%, 92%, and 100% respectively. MDCT had a sensitivity of 96%, a specificity of 96% and an accuracy of 96% when compared to the two dimensional transthoracic echocardiography using the 17-segment approach.

Conclusion: this study showed the feasibility of assessing global and regional LV function and LV volumes with Dual-Source 64-slice MDCT in patients with coronary artery disease during same data acquisition for noninvasive evaluation of the coronary arteries.

Keywords: Multidetector CT, global LV function, Regional wall motion, Ischemic heart disease, Echocardiography

INTRODUCTION

Two-dimensional transthoracic echocardiography (2D-TTE) is the most widely used method for LV function assessment, but the modality is operator dependent and can be impaired by a poor acoustic window.^[1]

Multidetector CT (MDCT) of the heart is used largely to evaluate the coronary arteries.^[2] Currently, MDCT is increasingly being considered as a potential tool for the assessment of the left ventricular function.^[3]

Retrospective electrocardiography (ECG)-gated MDCT allows for image reconstruction in any phase of the cardiac cycle. Thus, LV end-diastolic (ED) and end-systolic (ES) volumes can be assessed. In addition, ventricular wall motion can be assessed visually by the use of cine loop displays of multiple cardiac phases.^[4]

The aim of this work is to evaluate the diagnostic accuracy of dual source multidetector row computed tomography (MDCT) in assessment of global and regional left ventricular (LV) function in comparison with 2D-TTE.

PATIENTS AND METHODS

This observational analytical cross sectional study included 30 consecutive patients, with known or suspected coronary artery disease who were referred for dual-source 64 MDCT coronary angiography, for noninvasive evaluation of the coronary arteries. The study was conducted

in radiology department, National Heart Institute, Cairo, Egypt, in the period between May 2010 and November 2010. informed consent was obtained from all patients after explanation of the procedure, the study was approved by research and medical ethics committee.

The patients were examined thoroughly, with complete history taking and laboratory workup including: liver function test, kidney function test, ECG and X-ray chest, to exclude patients who were decompensated, with any contraindication for dye injection, any condition that will prevent the patient from holding his breathing for enough time to conduct the study, any rhythm other than sinus rhythm and any contraindications to x-ray exposure.

All MDCT examinations were performed with a dual-source 64-slice CT system (Somatom Definition, Siemens Medical Solutions, Forchheim, Germany) according to the routine protocol for coronary CT angiography.

All patients were fasting for at least 6 hours before the procedure. A peripheral IV access was secured (18G cannula) for injection of dye and medications.

All patients were premedicated with oral atenolol, with a dose ranging from 100 mg to 50 mg, according to the initial heart rate, one hour to 30 minutes prior to the scan, to bring the heart rate of the patient below 70 beat/min, additional 1-2

mg propranolol IV, was given during the scan, if the heart rate increased above 70 beats/min. All patients received an oral benzodiazepine, 1.5 mg bromazepam 15 – 30 minutes before the scan. A pre-exam testing of the ability of the patient to sustain a breath-hold for 10 to 15 seconds was preformed.

First step image acquisition to delineate the region of interest followed by a second step acquisition preceded by dye injection (nonionic iso-osmolar iodine containing contrast (Iopromide 370 mg /ml)) using a dual head injector (Optivantage DH, Covidien, Hampshire, UK), injecting in a rate of 5ml/second, automated scan was triggered by (sure-start feature) to time the scanning and the dye arrival to the heart. And simultaneous ECG tracing was obtained to allow automated gating of the images.

After all phases of the cardiac cycle were loaded to the computer, the software generated long-axis and short-axis displays of the heart. Left ventricular ejection fraction was calculated using semiautomated endocardial contour detection with manual correction when necessary. Papillary muscles were regarded as being part of the left ventricular cavity. LV ED and ES volumes were calculated using Simpson's method by summing the endocardial area of all LV ED and ES short-axis slices multiplied by the slice thickness. Segmental LV wall motion analysis was performed on horizontal and vertical long-axis views and short-axis cine loops. The short-axis view was evaluated at the basal, midventricular and apical positions along the long axis. Using the 17-segmental American Heart Association (AHA) model,^[5] each segment was assigned a wall motion score using a four-point scale (1=normokinesia, 2=hypokinesia, 3=akinesia, and 4=dyskinesia). Scans were analyzed by two observers unaware of the clinical data.

All patients underwent 2D-TTE, using a standard protocol. Echocardiographic examinations were performed on a GE Vivid 3 (GE Healthcare, Milwaukee, Wisconsin, USA). Patients will be imaged in the left lateral decubitus position. Images were acquired using 2: 3.5-MHz within 2-3 hours after the scan.

End-diastolic and end-systolic LVV and EF were calculated from the 2D-TTE by using Simpson's-method through manual endocardial tracing of the LV. Regional wall motion was

analyzed using 17-segment model as the same protocol used for MDCT.

Data were analyzed using SPSS software statistical package for social science version 16 (SPSS, Inc. Chicago, Illinois, USA). Data were expressed as the mean value \pm 1SD for continuous variables and as frequency (%) for categorical variables. Bland-Altman analysis was performed for each pair of values of left ventricular ejection fraction to calculate limits of agreement and systematic error between the two modalities.

RESULTS

The study group consisted of 15 (50%) females and 15 (50%) males. Their age ranged from 29 to 65 years with mean age 48.4 ± 10.1 years.

Mean left ventricular ejection fraction, as determined by 2D-TEE and MDCT, was $60.13 \pm 9.56\%$ and 58.3 ± 9.86 , respectively. The LVEF showed a highly significant positive correlation between the two modalities ($r = 0.966$, $p < 0.0001$), **Figure (1)**, And demonstrated a mean difference of $-1.8\% \pm 2.5\%$, which was not significantly different from 5- 95% limits of agreement, with clear tendency for under estimation in MDCT measurements, **Figure (2)**.

A total of 510 segments were evaluated by 2D-TTE and MDCT . In 2D-TTE, regional wall motion abnormalities were detected in 75 of 510 segments (14.7%); 47 (62.7%) showed hypokinesia, 24 (32%) showed akinesia, and 4 (5.3%) showed dyskinesia. MDCT detected 88 (17.2%) of 510 segments, abnormal wall motion was noted on the images; 54 (61.4%) showed hypokinesia, 28 (31.8%) showed akinesia, and 6 (6.8%) showed dyskinesia. Good agreement was shown between the two techniques, with 95.9% (489 of 510 segments) of the segments scored identically with use of both modalities. $\kappa = 0.85$ **Table (1)**

Using bimodal simplification, (normal & abnormal) agreement slightly increased to 96.3% (491 of 510 segments). $\kappa = 0.86$, **Table (2)**

Agreements for the individual gradings for the regional wall motion (normokinesia, hypokinesia, akinesia and dyskinesia) were 96%, 94%, 92%, and 100% respectively. When considering 2D-TTE as the "reference standard", MDCT had a sensitivity of 96%, a specificity of 96% and an accuracy of 96% using the 17-segment approach.^[5]

Table (1): Contingency table showing the relative agreement between Dual-source 64-slice MDCT and 2D-TTE for scores 1 to 4 per segment.

		MDCT score				Total
		1	2	3	4	
Echocardiograph score	1	419	10	6	0	435
	2	3	44	0	0	47
	3	0	0	22	2	24
	4	0	0	0	4	4
Total		422	54	28	6	510

Wall motion scores of 1 to 4 were assigned to the different segments:
 1=Normal wall motion; 2=Hypokinesia; 3=Akinesia; 4=Dyskinesia.

Table (2): Contingency table showing the relative agreement between Dual-source 64-slice MDCT and 2D-TTE for binary scores per segment.

		Wall Motion Segments Abnormality by MDCT		Total
		Normal	Abnormal	
Wall Motion Segments Abnormality by Echo	Normal	419	16	435
	Abnormal	3	72	75
Total		422	88	510

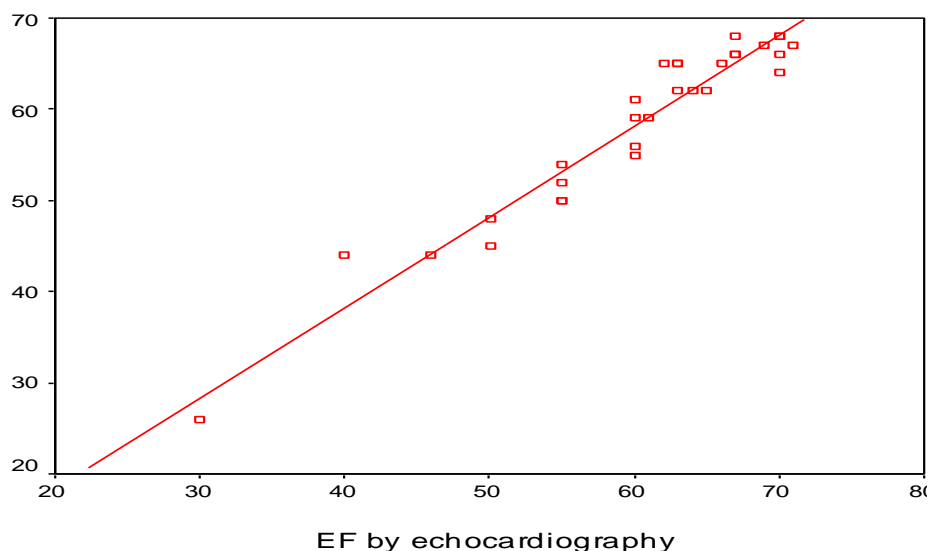


Figure (1): Linear regression plot shows the correlation between left ventricular ejection fraction (LVEF) measured by dual-source 64-slice multidetector CT (MDCT) and 2D-TTE.

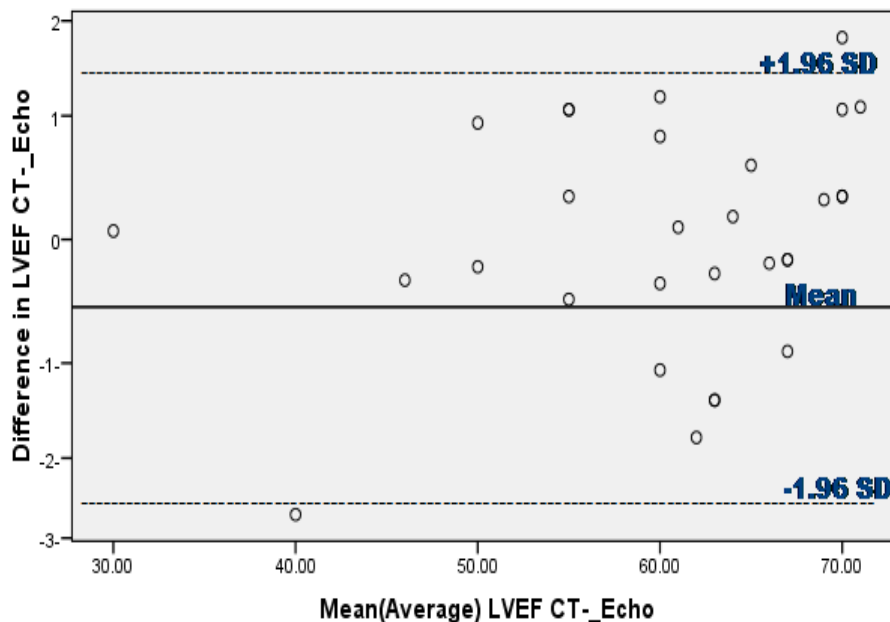


Figure (2): Bland–Altman plot of LVEF shows the difference between each pair plotted against the average value of the same pair and the mean value of difference.

DISCUSSION

The assessment of global and regional LV function and LV volumes is essential in the evaluation of patients with CAD. These parameters provide important information for clinical diagnosis, risk stratification, therapeutic strategy, and prognosis, as has been shown previously in numerous scintigraphic studies.^[6,7]

Although MDCT is unlikely to replace 2D-TTE for the assessment of LV function, it offers the unique ability to evaluate ventricular function and perfusion together with the coronary arteries in a single scan. It is also possible to view the anatomic relation between a coronary artery and the myocardium it supplies. MDCT enables excellent visualization of the endocardial surface as well as wall thickness and thickening, but its temporal resolution is far inferior to that of the 2D-TTE.^[8]

In our study LVEF was slightly underestimated with MDCT by an average of $1.8\% \pm 2.5\%$. Analysis of these results revealed a close correlation between These results are in agreement with previously published results by **Dirksen et al 2001**,^[9] who compared between the two methods in assessing left ventricular function in patients with unstable angina and found close correlation between the two modalities. The same results were obtained by **Mahnken et al 2003** and **Juergens et al 2004**.^[10,11]

It was noted in the present study that mean left ventricular ejection fraction as

determined by MDCT was slightly less than the echocardiographic results, but no statistical difference was reached between MDCT and 2D-TTE. Generally, end-systole was overestimated owing to the limited temporal resolution of MDCT and, subsequently, LVEF is then underestimated.^[12] This finding was concordant with previous reports that addressed the slight underestimation of left ventricular ejection fraction as determined by MDCT^[9-11]. This could be attributed to an overestimation of the LV end-systolic volume.

Echocardiography revealed contractile dysfunction in 75 of 510 segments (15%); 47 (63%) showed hypokinesia, 24 (32%) showed akinesia, and 4 (5%) showed dyskinesia. In 88 (17%) of 510 segments, abnormal wall motion was noted on the MDCT images; 54 (61%) showed hypokinesia, 28 (32%) showed akinesia, and 6 (7%) showed dyskinesia. Using 2D-TTE as the standard reference, the sensitivity was very high (96%), specificity was (96%) for the detection of regional dysfunction. By looking at these results, overall agreement of regional wall motion score was excellent; 96% of segments scored identically, $\kappa = 0.86$. The same results were obtained by **Henneman et al 2006**,^[13] who reported an agreement in 96% of the ventricular segments. However, MDCT scored a greater number of abnormal segments than 2D-TTE. These results are also in concordance with previously published reports.^[14-16]

In current study, agreements for the individual grading, [normokinesia, hypokinesia, akinesia, and dyskinesia(1-4)], were 96, 94, 92, and 100% respectively. The agreement for the individual wall motion scores was highest in the extremes (in segments with either normal contractility (96%) or dyskinesia (100%)), whereas it was slightly lower in segments showing intermediate contractile dysfunction. These results are concordant with ^[17] who found that agreements for the individual wall motion scores (1-4) were 97, 82, 73, and 92%, respectively.

CONCLUSION

In conclusion, this study shows the feasibility of assessing global and regional LV function and LV volumes with Dual-Source 64-slice MDCT in patients with known or suspected CAD. This information can be derived from the same data acquisition as used for the noninvasive evaluation of the coronary arteries.

Because MDCT is most likely to be applied as a first-line screening tool, baseline left ventricular function may be used to further refine risk stratification in the individual patient. However, it currently does not offer an alternative to echocardiographic examination because evaluation of valvular or diastolic function is not possible with MDCT.

REFERENCES

1. **Malm S, Frigstad S, Sagberg E, et al** (2004) "Accurate and reproducible measurement of left ventricular volume and ejection fraction by contrast echocardiography: a comparison with magnetic resonance imaging". *J Am Coll Cardiol.* 44:1030-1035.
2. **Vanhoenacker PK, Heijenbrok-Kal MH, Van Heste R, et al** (2007) "Diagnostic performance of multidetector CT angiography for assessment of coronary artery disease: meta-analysis". *Radiology;* 244:419-424.
3. **Orakzai SH, Orakzai RH, Nasir K, et al** (2006) "Assessment of cardiac function using multidetector row computed tomography". *J Comput Assist Tomogr;* 30:555-563
4. **Belge B, Coche E, Pasquet A, et al** (2006) "Accurate estimation of global and regional cardiac function by retrospectively gated multidetector row computed tomography. comparison with cine magnetic resonance imaging". *Eur Radiol.* 16:1424-1433.
5. **Cerqueira MD, Weissman NJ, Dilsizian V, et al** (2002) "Standardized myocardial segmentation and nomenclature for tomographic imaging of the heart: a statement for healthcare professionals from the Cardiac Imaging Committee of the Council on Clinical Cardiology of the American Heart Association". *Circulation;* 105(4): 539-542.
6. **Santana CA, Shaw LJ, Garcia EV, et al** (2004) "Incremental prognostic value of left ventricular function by myocardial ECG-gated FDG PET imaging in patients with ischemic cardiomyopathy". *J Nucl Cardiol.* 11: 542-550.
7. **Sharir T, Germano G, Kavanagh PB, et al** (1999) "Incremental prognostic value of post-stress left ventricular ejection fraction and volume by gated myocardial perfusion single photon emission computed tomography". *Circulation;* 100:1035-1042.
8. **Lessick J, Diab Mutlak, Shmuel Rispler, et al** (2005) "Comparison of Multidetector Computed Tomography Versus Echocardiography for Assessing Regional Left Ventricular Function". *Am J Cardiol.* 96:1011-1015.
9. **Dirksen MS, Bax JJ, de Roos A, et al** (2002) "Usefulness of dynamic multislice computed tomography of left ventricular function in unstable angina pectoris and comparison with echocardiography". *Am J Cardiol.* 90:1157-1160.
10. **Mahnken AH, Spuentrup E, Niethammer M, et al** (2003;) "Quantitative and qualitative assessment of left ventricular volume with ECG-gated multislice spiral CT: value of different image reconstruction algorithms in comparison to MRI". *Acta Radiol.* 44: 604-611.
11. **Juergens KU, Grude M, Maintz D, et al** (2004) "Multi-detector row CT of left ventricular function with dedicated analysis software versus MR imaging: initial experience". *Radiology;* 230:403-10.
12. **M Ko S, J Kim Y, H Park J, et al** (2010) "Assessment of left ventricular ejection fraction and regional wall motion with 64-slice multidetector CT: a comparison with two-dimensional transthoracic echocardiography". *The British Journal of Radiology;* 83: 28-34.
13. **Henneman MM, Schuijf JD, Jukema JW, et al** (2006) "Assessment of global and regional left ventricular function and volumes with 64-slice MSCT: a comparison with 2D echocardiography". *J Nucl Cardiol.* 13:480-7.
14. **Schuijf, J.D., et al** (2005) "Noninvasive coronary imaging and assessment of left ventricular function using 16-slice computed tomography". *Am J Cardiol.* 95; 571- 574.
15. **Schlosser T, Konorza T, Hunold P, et al** (2004) "Noninvasive visualization of coronary artery bypass grafts using 16-detector row computed tomography". *J Am Coll Cardiol.* 44(6):1224-1229.
16. **Halliburton SS, Stillman AE, Flohr T, et al** (2003) "Do segmented reconstruction algorithms for cardiac multi-slice computed tomography improve image quality?" *Herz.* 28:20-31.
17. **Schuijf JD, Bax JJ, Jukema JW et al** (2004) "Non-invasive angiography and assessment of left ventricular function using multislice computed tomography in patients with type 2 diabetes". *Diabetes care;* 27: 2905-2910.

دور الأشعة المقطعية ثنائية المصدر متعددة الكواشف في تقييم وظيفة البطين الأيسر الكلية والإقليمية مقارنة بصدي القلب ثنائي الأبعاد

نادر طلعت قنديل⁽¹⁾، هشام سمير رشدي⁽¹⁾، منتصر مصطفى الصقلي⁽¹⁾، أحمد صبري السعيد⁽²⁾
قسم القلب والأوعية الدموية،⁽¹⁾ كلية الطب جامعة الزقازيق،⁽²⁾ معهد القلب القومي، أمابيه، القاهرة.

يستخدم التصوير المقطعي متعدد الكواشف حالياً إلى حد كبير لتقييم تشريح الشرايين التاجية. ولم يعتمد عليه حتى الآن في تقييم وظيفة البطين الأيسر. تهدف هذه الدراسة إلى تقييم الدقة التشخيصية للتصوير المقطعي في تقييم الوظيفة الكلية والإقليمية للبطين الأيسر بالمقارنة مع تخطيط صدى القلب. وفي هذا السياق تمت مقارنة نتائج تقييم الأشعة المقطعية متعددة الكواشف للوظيفة الانقباضية و الشذوذ الإقليمي في حركة البطين الأيسر بالنتائج المستقاه من تخطيط صدى القلب في ثلاثين مريضاً علي التوالي. أظهرت مقارنة النتائج فيما يخص تقييم الوظيفة الكلية للبطين الأيسر ارتباطاً إيجابياً قوياً ذو دلالة إحصائية عالية بين كل من التقنيتين، كما كان متوسط الاختلاف بين التقنيتين فيما لا يزيد عن ١,٨%، وفيما يختص بتقييم الوظيفة الإقليمية وجد اتفاق جيد بين الطريقتين، فقد تطابقت النتائج في ٤٨٩ قطاعاً مدروساً من أصل ٥١٠ قطاعاً، بنسبة تطابق تصل إلى ٩٥,٩%. كما تطابقت الدرجات الفردية لحركة الجدار الإقليمية وكانت نسبة التطابق كالاتي: الحركة الطبيعية بنسبة ٩٦%، تقييد الحركة ٩٤%، تعذر الحركة ٩٢% انعكاس الحركة ١٠٠%. كما أوضحت الدراسة بأن التصوير المقطعي متعدد الكواشف يتمتع بحساسية تصل إلى ٩٦%، وخصوصية تصل إلى ٩٦% ودقة تصل إلى ٩٦% بالمقارنة مع تخطيط صدى القلب ثنائي الأبعاد باستخدام نهج تقسيم البطين الأيسر إلى ١٧ جزءاً. في الختام، أظهرت هذه الدراسة جدوى استخدام الأشعة المقطعية متعددة الكواشف لتقييم وظيفة البطين الأيسر الكلية والإقليمية في المرضى الذين يعانون من مرض الشريان التاجي خلال الحصول على البيانات لتقييم تشريح الشرايين التاجية.