

SURGICAL VERSUS INTERVENTIONAL THERAPY OF NATIVE AND RECURRENT AORTIC COARCTATION IN CHILDHOOD

By

Heba MH Abozeid .

Lecturer of Pediatrics , Pediatric Department , Zagazig University

ABSTRACT

Background: The long-term results of coarctation (CoA) whether native or recurrent , have been described for adolescents and adults , but the influence of age, especially in the younger pediatric population, on the outcome of treatment has not been fully determined .**Objective:** The aims of the study were: 1- To analyse immediate results, rate of complications and re-interventions after medium-term follow up in pediatric patients with native or recurrent aortic coarctation 2- To evaluate the age-related therapeutic approach for CoA . **Methods:** This is a retrospective, single centre, clinical observational trial .This work focused on an age-related therapeutic approach comparing surgical and trans-catheter treatment including 51 patients (age:5 days-14 years) treated for native coarctation. **Results:** Studied patients were divided into 3 groups based on their age; 24 children in group I (< 6 months of age), 11 in group II (6 months-6 years), and 16 in group III (> 6 years) .Medical records, angiographies, echocardiographic and hemodynamic data were reviewed. Further follow-up was obtained by clinical evaluation (blood pressure gradient between upper and lower extremities).Twenty six surgical procedures were performed (25 for native and 1 for re-COA) , 60 balloon dilatations (51 for native and 9 for re-COA) and 14 stent implantations were made (all for native COA). Fifty one balloon dilatations were initially made for native coarctation (24 in group I , 11 in group II &16 in group III) of which 14 patients underwent stent implantation (1 in group I , 1 in group II &12 in group III) and 25 patients were surgically repaired (20 in group I & 5 in group II). A significant drop of pressure gradient occurred in all age groups (71.7% in group I , 69.7 % in group II, and 66.5 % in group III). Rate of surgical complication & rate of re-intervention were comparable among the three age groups (complications: group I; 8.3 % , group II; 9.1 %,and group III; 6.25 % ; re-intervention rates were 20.8%, 18.2%, and 18.75% in groups I , II & III respectively). **Conclusions:** A convenient strategy of an age-related therapy for native and recurrent aortic coarctation is surgery in infants <6 months (group I), either surgery or balloon dilatation in patients 6 months-6 years (group II),while in older children >6 years of age (group III) the trans-catheter treatment with stent implantation is an excellent alternative to surgery.

INTRODUCTION

Patients with coarctation of the aorta (CoA) may present at any age, but most present in infancy or early childhood. Surgery is usually performed in infants diagnosed under 1 year of age. After infancy, interventional techniques are chosen over surgery as they are less invasive and result in less procedure-related morbidity (1). Angioplasty is most often the treatment of choice in small children, whereas stent implantation is usually preferred in older patients. Although reports of stent implantation in older patients with CoA demonstrate immediate results superior to angioplasty with fewer complications, angioplasty without stent implantation continues to be preferred

in small children (2- 6). However, different clinical studies comparing these three therapeutic options show conflicting data (7-13). The long-term results of CoA, either native or recurrent, have been described for adolescents and adults (14,15), but the influence of age, especially in the younger pediatric population, on the outcome of treatment of CoA , has not been fully determined. Neonates and infants with native CoA are usually treated by surgery while older children and adolescents are treated by stent implantation. Balloon dilatation is performed mainly in recurrent aortic coarctation (Re-CoA), especially in neonates and infants. Therefore, the aims of our study were to evaluate this age related approach by comparing the results

of the three treatment strategies: surgery, balloon dilatation, and stent implantation and to analyse immediate results, rate of complications and re-interventions after medium-term follow up in pediatric patients with native or recurrent aortic coarctation

PATIENTS AND METHODS

The study was designed as a single-center, clinical, retrospective ,observational trial. All consecutive patients treated for native CoA and Re-CoA between September 2002 and September 2008 at King Faisal Specialist Hospital and Research Center (KFSH&RC)-Jeddah with an age younger than or equal to 14 years were included. All patients included in the study had the cardiac diagnosis of an isolated native CoA or Re-CoA, either after surgery or after catheter-based therapy, figure-1. Concomitant minor cardiac anomalies, for example, small ventricular septal defect (VSD), atrial septal defect (ASD) ,or mild aortic valve stenosis (AS, systolic pressure gradient ≤ 20 mmHg) were included, while all children with other major cardiac anomalies, for example, patients with hypoplastic left heart syndrome, were excluded. Medical records, angiographies, echocardiographic and hemodynamic data were reviewed. Further follow-up was obtained by clinical evaluation (blood pressure gradient between upper and lower extremities).The indications for treatment of native CoA & Re-CoA were similar with (1)systolic blood pressure gradient of more than 20 mmHg between arms and legs ,(2) an arterial hypertension of the upper extremities at rest or during exercise in absence of other causes of arterial hypertension), and (3)signs of left ventricular hypertrophy in echocardiography. To compare the age-related therapy for native CoA and Re-CoA, we arbitrarily divided our patients into three groups according to their age with group I less than 6 months, group II between 6 months and 6 years ,and group III between 6 and 14 years of age.

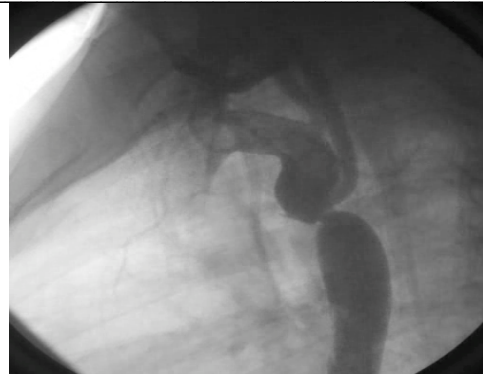

Figure-1:An aortogram in a twelve year old patient showing discrete CoA
Catheter interventions

Cardiac catheter interventions were performed under general anaesthesia or conscious sedation. Percutaneous vessel access was achieved in all cases via the femoral artery. Heparin (100 units/ kg) was given after successful arterial access, and repeated after 1 h (50 units/kg). The coarctation was crossed in a retrograde manner with a diagnostic catheter, and peak pressure gradients between the ascending aorta and the descending aorta were measured. Angiography of the coarctation was performed and recorded in the left anterior oblique (LAO 10-20 degrees) and straight lateral projections .The following bilateral measurements were performed : smallest diameter of the coarctation; diameter of the transverse aortic arch; and diameter of the aorta proximal and distal to the site of coarctation. The diameter of the balloon used for dilatation was chosen equal to the diameter of the transverse aortic arch. Dilatation was performed over a period of 10 s. Stent implantation was performed via retro-grade approach using a long sheath, which allowed a proper stent positioning and hand injections of contrast medium during implantation (16). Immediately after balloon dilatation or stent implantation, the invasive residual pressure gradient was measured and angiography was performed.

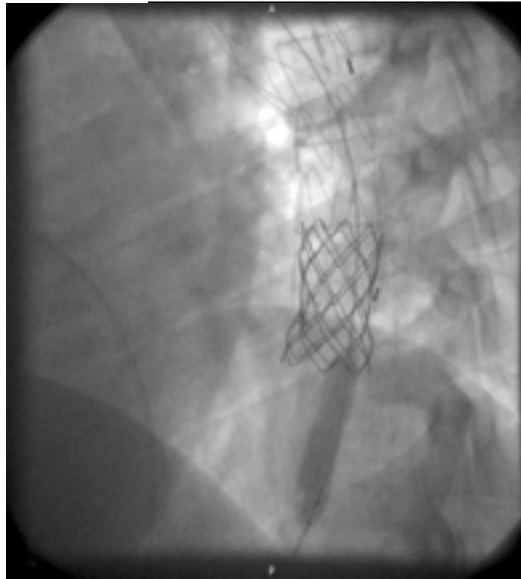

Figure 3: Stent implantation and balloon inflation in one of our patients with native CoA.

Follow-up

At the time of early (24 hours after intervention) and late (last follow-up) follow up, Doppler echocardiographic gradients were measured. Significant early and late complications of the procedures were chylothorax and transient loss of femoral pulse. Re-intervention was defined as secondary surgical or catheter interventional redo after a successful primary intervention. Hemodynamic indication for re-intervention was a systolic pressure gradient of more than 20 mmHg across the recoarctation of the aortic arch.

Statistics

Table-1

Therapy For Native Co-A

Results are presented as mean and standard deviations or as median and ranges, as appropriate. For comparisons of Doppler gradients before and at day1 after intervention, we used the Wilcoxon signed-rank test for each age group. For comparison of the performed procedure (surgery, balloon dilatation, or stent implantation), we used the Mann-Whitney U test to compare two procedures; and the Kruskal-Wallis one-way analysis of variance was used to compare all three procedures. Analyses were performed using Statistical Package for Social Sciences (SPSS) 16 (SPSS Inc., Chicago , IL, USA).A p value less than 0.05 was considered as significant.

RESULTS

We enrolled 51 patients (33males) treated for CoA (of which 10 patients had Re-CoA).The median age at the time of the intervention was 4.9 months (range 5 days-14years).The patients were treated either by surgery (n = 25) or by interventional catheterization (balloon dilatation; n = 51 and stenting ; n=14, table-1). A total of 24 Table-1 Methods of treatment & ratio of re-intervention for CO-A in different age groups(N=51).

Group I (N=24)			Group II (N=11)			Group III (N=16)		
Surgery	Balloon	Stent	Surgery	balloon	Stent	surgery	balloon	stent
N=20	N=24	N=1	N=5	N=11	N=1	N=0	N =16	N=12
Reintervention	Noreintervention	Reintervention.	Noreintervention	Reintervention	Noreintervention	Reintervention	Noreintervention	
N=5	N=19	N=2	N=9	N=3	N=3	N=13		
(20.8 %)	(79.2%)	(18.2%)	(81.8%)	(18.75%)	(81.25%)			

Table-2
Re-Intervention For Re-Coa In Different Age Groups

procedure	Group I (N=5)			Group II (N=2)			Group III (N=3)		
	Surgery	Balloon	stent	Surgery	Balloon	stent	Surgery	Balloon	stent
N	1	4	0	0	2	0	0	3	0
%	20	80	0	0	100	0	0	100	0

Table-3
Surgery Vs Trans-Catheter Therapy of CoA

Therapeutic Method	Group I (N=24)		Group II (N=11)		Group III (N=16)	
	Surgery(N=20)	Trans-catheter (N=4)	Surgery(N=5)	Trans-catheter (N=6)	Balloon dilatation (N=4)	Stent implantation (N=12)
PG pre-day1 (mmHg)	36.6±17.3	48 ±7.3	41±9.5	43±8.1	39.8±16.3	43.3±15.5
PG post-day1 (mmHg)	10.9±8	31.5 ±18.6	16 ±7.2	17± 8.5	35.7±11.2	11.4±10
PG drop (%)	70.2%	34.4 [#]	60.1	60.5	10.3	73.7%*

PG=pressure gradient , [#] =p < 0.05 for surgery vs trans-catheter therapy in group I , * = p < 0.05 for balloon dilatation vs stent implantation in group III.

Table-4 **Medium-term follow up results**

	Group I(n=24)	Group II(n=11)	Group III(n=16)
Doppler Gradient Pre (mmHg)	42.4±15.1	47±14.2	48±13.2
Doppler Gradient Post-day 1 (mmHg)	12±10.7*	14.2±13.1*	16.1±14.3*
Rate of gradient reduction (%)	71.7%	69.7%	66.5%
Rate of complications % (n)	8.3% (2)	9.1% (1)	6.25% (1)
Rate of re-intervention % (n)	20.8% (5)	18.2% (2)	18.75 % (3)

Data are given as mean and standard deviation. Wilcoxon signed-rank test was used for comparison of Doppler gradient pre versus post-day1. * = p < 0.05.

children were treated at an age <6 months (group I), 11 children were treated at an age between 6 months and 6 years (group II), and 16 older children and adolescents were treated at an age >6 years (group III), table-1. The follow up period for the whole patient group was 21.5 months (range 3 days -56 months). Two patients younger than 6 years of age (1 in group I & 1 in group II) with native CoA were treated by stent implantation instead of surgery as rescue procedures due to severe congestive heart failure.

Cardiac surgery

Within enrolled children, 25 (16 males) underwent cardiac surgery. The median age of this group was 23 months (range 5 day-6 years) and median weight 6.2 kg (2.1-19 kg). The surgical access was left-sided posterior thoracotomy. The surgical technique was an extended end-to-end anastomosis .

Catheter interventions

Trans-catheter interventions were balloon angioplasty performed in 51 patients ,and stent implantation in 14 patients as balloon dilatation was attempted before either stenting or surgery, table-1 .The median age was 134.4 months (range 35 days-13 years) and median weight 31 kg (3-62 kg).

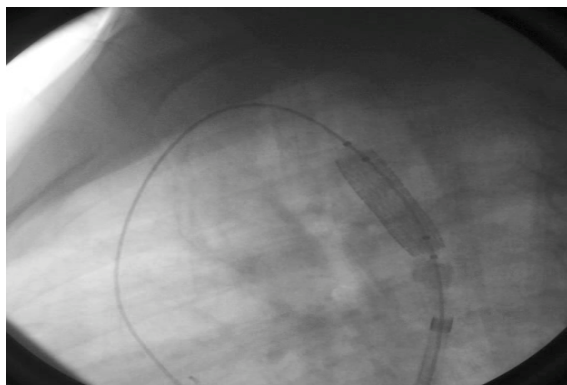


Figure 2: Balloon dilatation of CoA in one of our patients

Children < 6 years of age treated by catheter interventions mainly underwent balloon angioplasty (9 of 11 ,81.8%),figure-2, whereas in the group of children > 6 years of age (group III) stent implantation predominated (12 of 16 , 75%), table-1, figure-3.The median

diameter of the used balloons was 8 mm (range 5-14 mm). Those balloons had a low pressure profile with a maximum pressure of 3.5 atm to be achieved during dilatation. Platinum (CP) Stents (NuMed Inc., Nicholville, NY, USA) were used in 9 patients & Palmaz Genesis Stents (Johnson & Johnson Interventional System, Somerville, NJ, USA) in 5 patients. Comparing the type of procedure (surgery, balloon dilatation ,or stent implantation), we found a more significant decrease of Doppler gradient in group I patients treated by surgery (70.2%) compared with those treated by balloon dilatation (34.4%) ,table-3.No differences between the three types of procedures were found in group II .In group III ,we found a significant decrease of Doppler gradient in patients treated by stent implantation (73.7%) compared with balloon dilatation (10.3%) ,table-3 . A significant reduction of Doppler gradient was achieved in all three age groups (71.7% in group I , 69.7% in group II, and 66.5% in group III, p values < 0.05 ,table 4).

In the whole patient group, re-interventions became necessary in 10 patients including 5 patients in group I , 2 patients in group II and 3 patients in group III (table-2).Re- interventions were performed after a median time interval of 4 months (range 1 -50 months) of the primary intervention .In all other patients, after a median follow-up of 21.5 months , there was no significant increase of Doppler gradients. Complications occurred in 2 patients of group I (8.3%) .Chylothorax requiring tube drainage occurred in one patient postoperatively.Transient loss of femoral pulse occurred in 3 patients after trans-catheter intervention (one patient in each age group, table-4) & was treated with IV heparin infusion. There was no mortality associated with surgery,trans-catheter treatment or redo intervention.

Study Limitations

This study is limited by its retrospective and non-randomized design, the relatively low number of patients in the subgroups, and only medium-term follow-up time. Isolated CoA maybe associated with borderline hypoplasia of parts of the transverse aortic arch. Therefore, these borderline patients were included in this series.

DISCUSSION

There is no age-related strategy in our center for management of Co-A but the trend is surgery in infants if balloon dilatation fails and primary trans-catheter treatment with stent implantation in older children. The indication for surgery instead of balloon dilatation or stent implantation is given in case of associated severe aortic arch hypoplasia or associated cardiac anomalies requiring surgery. Primary treatment at any age, either by surgery or by trans-catheter treatment, leads to a significant and lasting reduction of the pressure gradient across the aortic arch. Acceptable complication rates of 8.3% in group I (<6 months), 9.1% in group II (6months-6years) & 6.25% in group III (>6 years), are comparable with (17). Re-intervention rates of 20.8, 18.2& 18.75% are also comparable with the results reported of other studies, (7,9,17&18), table-4.

In the very young patients < 6 months of age (group I), the early and long-term results of surgical resection are excellent. These data confirm surgery as the treatment of choice in this specific age group. Wood et al. have shown excellent long-term results after extended arch aortoplasty confirming our data (19). Some studies comparing surgery and balloon dilatation showed significantly lower re-intervention and complication rates after surgery than after balloon angioplasty (7,9,18). In some institutions, percutaneous procedures in this age group mainly serve as a rescue therapy for patients in severe heart failure, to stabilize their clinical condition and bridge them to definitive

surgical correction later on. We performed either rescue balloon angioplasty (n = 4) or stent implantation (n = 1) in these high-risk patients with a good initial relief of the pressure gradient without significant morbidity or mortality.

In children between 6 months and 6 years of age (group II) with isolated CoA, the immediate results of reduction of gradients by surgery & angioplasty are comparable table-3, in agreement with other series (20,21). Long term follow-up using magnetic resonance imaging (MRI) is recommended to detect aneurysm formation even years after primary or secondary intervention (7). Stent implantation is not recommended in this age group due to the need for frequent redilatation in growing children, the lack of redilatable stents until adulthood, a high incidence of intimal proliferation in small stents and the potential development of post-stent aneurysm formation (16).

In children > 6 years of age (group III), stent implantation is an excellent therapeutic alternative to surgery. Stents have the unique property to avoid elastic recoil of the vessel wall and to fix and stabilize the dissected intima and, by this, minimize the risk for aortic rupture and aneurysm formation. Previous studies have shown the safety of stent implantations in adolescents with excellent medium-term outcomes (9, 22-25). In our series, stent implantation was performed successfully with a low rate of re-interventions and no complications similar to other studies (10, 22,26). This interventional approach is suitable for native CoA as well as for Re-CoA and the results are comparable to those of surgery. Further redilatation after stent implantation is needed due to somatic growth of children.

Promising new devices such as the growth stent or biodegradable stents have been developed (27). Possibly, they might help to perform successful and durable trans-catheter interventions in early childhood and, by this, replace a certain amount of surgical procedures in these

patients. The CP stent (NuMed Inc., Nicholville, NY, USA), is preferred as it enables redilatation sufficient for adult aortic sizes (28). This platinum stent has high radial forces, good tissue tolerance, optimal adhesion to the vessel wall, low fracture rates during follow-up, acceptable stent shortening during redilatation, and MRI compatibility (21,28). It has been shown that serial dilatations of the CP stent, either covered or uncovered, are feasible, safe, and effective (21). Covered stents are favoured in adult patients or after aortic dissection. In our opinion, in patients with a complex CoA / Re-CoA with hypoplasia of the aortic arch, surgery is, in most cases, a safe & a more effective approach. In the future, further prospective, multicenter trials are needed to investigate the medium-and long-term outcome of surgical and trans-catheter treatment for pediatric patients in different age groups .

REFERENCES

- 1- Rodés-Cabau J, Miro´ J, Dancea A. Comparison of surgical and transcatheter treatment for native coarctation of the aorta in patients >1 year old. The Quebec Native Coarctation of the Aorta study. *Am Heart J* 2007;154:186–92.
- 2- Golden AB, Hellenbrand WE. Coarctation of the aorta: stenting in children and adults. *Catheter Cardiovasc Interv* 2007;69:289–99.
- 3- Ovaert C, Benson LN, Nykanen D, Freedom RM. Transcatheter treatment of coarctation of aorta: a review. *Pediatr Cardiol* 1998;19: 27–44.
- 4- Fletcher SE, Nihill MR, Grifka RG, OLaughlin MP, Mullins CE. Balloon angioplasty of native coarctation of aorta: mid term follow up and prognostic factors. *J Am Coll Cardiol* 1995;25:730–4.
- 5- Patel HT, Madani A, Paris YM, Warner KG, Hijazi ZM. Balloon angioplasty of native coarctation of the aorta in infants and neonates: is it worth the hassle? *Pediatr Cardiol* 2001;22:53–7.
- 6- McCrindle BW, Jones TK, Morrow WR. Acute results of balloon angioplasty of native coarctation versus recurrent aortic obstruction are equivalent. Valvuloplasty and Angioplasty of Congenital Anomalies (VACA) Registry Investigators. *J Am Coll Cardiol* 1996;28:1810–7.
- 7- Cowley CG, Orsmond GS, Feola P, McQuillan L, Shaddy RE. Long-term, randomized comparison of balloon angioplasty and surgery for native coarctation of the aorta in childhood. *Circulation* 2005; 111:3453–6.
- 8- Hernandez-Gonzalez M, Solorio S, Conde-Carmona I, Rangel-Abundis A, Ledesma M, Munayer J, David F, Ortegon J, Jimenez S, Sanchez-Soberanis A, Melendez C, Claire S, Gomez J, Teniente-Valente R, Alva C. Intraluminal aortoplasty vs. surgical aortic resection in congenital aortic coarctation. A clinical random study in pediatric patients. *Arch Med Res* 2003;34:305–10.
- 9- Pedra CA, Fontes VF, Esteves CA, Pilla CB, Braga SL, Pedra SR, Santana MV, Silva MA, Almeida T, Sousa JE. Stenting vs. balloon angioplasty for discrete unoperated coarctation of the aorta in adolescents and adults. *Catheter Cardiovasc Interv* 2005;64:495–506.
- 10- Rodes-Cabau J, Miro J, Dancea A, Ibrahim R, Piette E, Lapierre C, Jutras L, Perron J, Tchervenkov CI, Poirier N, Dahdah NS, Houde C. Comparison of surgical and transcatheter treatment for native coarctation of the aorta in patients > or =1 year old. The Quebec Native Coarctation of the Aorta study. *Am Heart J* 2007;154:186–912.
- 11- Shaddy RE, Boucek MM, Sturtevant JE, Ruttenberg HD, Jaffe RB, Tani LY, Judd VE, Veasy LG, Mc-Gough EC, Orsmond GS. Comparison of angioplasty and surgery for unoperated coarctation of the aorta. *Circulation* 1993;87:793–9.
- 12- Wong D, Benson LN, Van Arsdell GS, Karamlou T, McCrindle BW. Balloon angioplasty is preferred to surgery for aortic coarctation. *Cardiol Young* 2008;18:79–88.
- 13- Zabal C, Attie F, Rosas M, Buendia-Hernandez A, Garcia-Montes JA. The adult patient with native coarctation of the aorta: balloon angioplasty or primary stenting? *Heart* 2003;89:77–83.
- 14- Hoimyr H, Christensen TD, Emmertsen K, Johnsen SP, Riis A, Hansen OK, Hjortdal VE. Surgical repair of coarctation of the

- aorta: up to 40 years of follow-up. *Eur J Cardiothorac Surg* 2006;30:910—6.
- 15- Walhout RJ, Suttorp MJ, Mackaij GJ, Ernst JM, Plokker HW. Long-term outcome after balloon angioplasty of coarctation of the aorta in adolescents and adults: is aneurysm formation an issue? *Catheter Cardiovasc Interv* 2009;73:549—56.
- 16- Bulbul ZR, Bruckheimer E, Love JC, Fahey JT, Hellenbrand WE. Implantation of balloon-expandable stents for coarctation of the aorta: implantation data and short-term results. *Catheter Cardiovasc Diagn* 1996;39:36—42.
- 17- Seraina Fruh , Walter Knirsch, Ali Dodge-Khatami a, Hiten du Dave a, Rene' Pretre a, Oliver Kretschmar. Comparison of surgical and interventional therapy of native and recurrent aortic coarctation regarding different age groups during childhood. *Europ J Cardio thorac Surg* 2010;97;651-8 .
- 18- Suarez de Lezo J, Pan M, Romero M, Segura J, Pavlovic D, Ojeda S, Algar J, Ribes R, Lafuente M, Lopez-Pujol J. Percutaneous interventions on severe coarctation of the aorta: a 21-year experience. *Pediatr Cardiol* 2005;26:176—89.
- 19- Wood AE, Javadpour H, Duff D, Oslizlok P, Walsh K. Is extended arch aortoplasty the operation of choice for infant aortic coarctation? Results of 15 years' experience in 181 patients. *Ann Thorac Surg* 2004;77:1353—8.
- 20- Ovaert C, McCrindle BW, Nykanen D, MacDonald C, Freedom RM, Benson LN. Balloon angioplasty of native coarctation: clinical outcomes and predictors of success. *J Am Coll Cardiol* 2000;35:988—96.
- 21- Pandey R, Jackson M, Ajab S, Gladman G, Pozzi M. Subclavian flap repair: review of 399 patients at median follow-up of fourteen years. *Ann Thorac Surg* 2006;81:1420—8.
- 22- Hamdan MA, Maheshwari S, Fahey JT, Hellenbrand WE. Endovascular stents for coarctation of the aorta: initial results and intermediate-term follow-up. *J Am Coll Cardiol* 2001;38:1518—23.
- 23- Harrison DA, McLaughlin PR, Lazzam C, Connelly M, Benson LN. Endovascular stents in the management of coarctation of the aorta in the adolescent and adult: one year follow up. *Heart* 2001;85:561—6.
- 24- Magee AG, Brzezinska-Rajszyz G, Qureshi SA, Rosenthal E, Zubrzycka M, Ksiazzyk J, Tynan M. Stent implantation for aortic coarctation and recoarctation. *Heart* 1999;82:600—6.
- 25- Pedra CA, FontesVF, Esteves CA, Arrieta SR, Braga SL, Justino H, Kambara AM, Moreira SM, Sousa JE. Use of covered stents in the management of coarctation of the aorta. *Pediatr Cardiol* 2005;26:431—9.
- 26- Mahadevan VS, Vondermuhll IF, Mullen MJ. Endovascular aortic coarctation stenting in adolescents and adults: angiographic and hemodynamic outcomes. *Catheter Cardiovasc Interv* 2006;67:268—75.
- 27- Schranz D, Zartner P, Michel-Behnke I, Akinturk H. Bioabsorbable metal stents for percutaneous treatment of critical recoarctation of the aorta in a newborn. *Catheter Cardiovasc Interv* 2006;67:671—3.
- 28- Dodge-Khatami A, Backer CL, Mavroudis C. Risk factors for recoarctation and results of reoperation: a 40-year review. *J Card Surg* 2000;15:369—77.