

## PULMONARY COMPLICATIONS OTHER THAN TUBERCULOSIS IN HIV PATIENTS IN MANSOURA FEVER HOSPITAL.

*Ahmed Saad Elmorsy\**, *Mohamed Hossam Eldeen Zaghloul\*\**, *Nessrin Mohmmmed Shalaby<sup>8</sup>\**,  
*Asem Abdelhamid Hewidy\**, *Heba Abd Elhameed El-shahawy\*\**, *Nagwa Ibrahim Mosaad Elhalawany\**

*Chest Medicine\* and Clinical Pathology\*\* departments, Faculty of Medicine - Mansoura University - Egypt*

### Corresponding Author:

Nagwa Ibrahim Mosaad -  
01222206704 -  
negm\_gogo2010@yahoo.com  
, negmgog2010@gmail.com.

### ABSTRACT

**Background:** A remarkable cluster of *Pneumocystis carinii* pneumonia and Kaposi's sarcoma male cases with history of homosexuality first described in 1981, since that period fundamental improvement in understanding this acquired immune deficiency syndrome (AIDS) have been carried out [1].

**Aim:** The aim of this study was to evaluate the pulmonary complications in patients with HIV.

**Patients and Methods:** A descriptive study conducted on 200 seropositive HIV adult patients screened for chest problems; 76 patients of them were included, and then TB infection has been excluded in 53 patients (70%).

**Results:** Acute bronchitis (36%), community acquired pneumonia (CAP) (24%), chronic obstructive airway diseases (15%) and infective endocarditis (8%) in addition to malignancy were the manifested complications in those patients.

**Conclusion:** HIV patients with advanced immune suppression are vulnerable group for chest complications from acute bronchitis to malignancy.

**Key words:** HIV; human immune deficiency virus, TB; tuberculosis, CAP; community acquired pneumonia.

### INTRODUCTION

**A**cytopathic retrovirus has been identified in 1983 and it has called Human immunodeficiency virus (HIV) differentiating it from Simian immunodeficiency virus that infect chimps, with evolution of serologic test for HIV diagnosis in 1985 which has formed a corner stone in diagnostic amelioration. While dramatic alteration of development of antiretroviral drugs (ART) has been started in 1987 [2].

AIDS has been defined in 1987 as collective conditions indicating severe immunosuppression, specifically decreased cell-mediated immunity. Although decreasing humoral immunity as CD4 T cells wane by time, B cells show proliferation and increased

markers of activation while the recovery of humeral immunity is achieved only by starting ART [1].

Infection of the lung cells as pulmonary lymphocytes and macrophages by HIV has the main role in pulmonary disease pathogenesis in those patients. This infection referred as a state of "viral compartmentalization" by which there is a genetic variant of HIV virus infecting lung different from that in blood this is may result from specific lung recruitment of that strain [3].

In contrast to replication in serum there is a slow growth rate of HIV in the lung during the latent stage of the disease, while marked increase in replication occur during development of any pulmonary disease even exceeding the serum growth. Although the

studies as regard immunity in HIV concentrating on the adaptive immunity, there is marked alteration in innate immunity as well. This affection of innate immunity presents in a unique manner not depending on CD4 count or even viral load as it may be manifested with high CD4 and undetectable load [4].

This alteration of innate immunity is the cause of recurrent pneumonia and potentiating the risk of developing TB in early stages while in late stages defective innate immunity together with the decreased CD4+ T cell count leading to opportunistic infections of lung [5].

There are manifested innate immunity defects on studying the response of HIV infected patients to different bacterial pathogen. However no apparent defect in phagocytosis by the alveolar macrophages, so, other mechanisms may be influenced [6].

The lung has been recognized from the beginning of the disease as one of the main targets of infectious and non-infectious complications of AIDS. The spectrum of lung diseases in HIV patients include HIV linked complication such as TB, recurrent pneumonia, lymphomas and HIV associated pulmonary hypertension, in addition to usual respiratory diseases as uninfected population as bronchitis, bronchial asthma, COPD, and bronchial carcinomas. While classically associated HIV complications as PCP and Kaposi sarcoma have become rare by the effect of ART and guidelines for chemoprophylaxis and other complications have take place [7].

In view of the high smoking prevalence and risk for lung cancer in HIV patients, this population is expected to have an increased need for screening CT in the near future. Whether HIV infection should be regarded as an additional lung cancer risk factor and prompt screening at younger ages in this population has been debated [8].

Asthma and COPD are of higher prevalence in PLWH than non HIV. Spirometric screening

and diffusion capacity testing might be of benefit in HIV population especially those with smoking history or presents with symptoms suggestive for obstruction. Taking into account special considerations as regard ART as protease inhibitors may result in accumulation of inhaled steroids and could increase risk of pneumonia [9].

#### **PATIENTS AND METHODS**

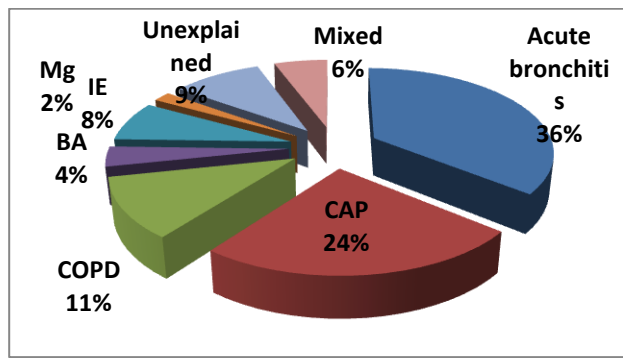
A descriptive study conducted on 200 seropositive HIV adult patients screened for chest problems in the period between October 2015 to October 2016; 76 patients of them were included, and then TB infection has been excluded by ZN staining, TB culture and GeneXpert in 53 patients (70%).

**Results:** The complications had shown in fig. 1.

There were 19 patients (36%) presented by acute bronchitis, 13 patients (24%) presented by community acquired pneumonia (CAP) where 4 patients of them were specific pneumonia (2 klebsiela, 1 Pseudomonas both were diagnosed by BAL culture and PCP diagnosed by responding only on Co-trimoxazole (therapeutic test) as the patient was not fit for bronchoscopy). Infective endocarditis (IE) was diagnosed in 4 (8%) patients were presented by bilateral multiple cavities and diagnosed by ECHO.

There was one (2%) patient presented by extensive bilateral pulmonary infiltrates with mediastinal lymphadenopathy diagnosed as lymphoma by pathology of cervical lymph node exisional biopsy, 4 (6%) patients were have more than one diagnosis (mixed) [CAP with Cryptococcus meningitis, CAP with Cerebral toxoplasmosis and lymphoma with CAP].

COPD was presented in 6 males' smoker patients (11%), while there were 2 asthmatic female patients (4%). There were 5 (9%) patients presented by unexplained fever and or weight loss that mostly related to HIV as become well with antiretroviral therapy.



**Figure 1: Pulmonary complications in HIV patients other than tuberculosis.**

### DISCUSSION

New statistics from Sub-Saharan Africa have shown 33 percent decline in annual new HIV cases since 2005. While in the Middle East and North Africa (MENA) region it has been increased by 31 percent, that is represent the highest between all regions of the world (In 2015, MENA region has been estimate, 230000 people living with HIV and 21000 new HIV infections) [10].

Acute bronchitis represented by 19 (36%) and 13 (24%) presented by CAP where 4 patients (30.8%) of them were specific pneumonia (2 klebsiela, 1 Pseudomonas both were diagnosed by BAL culture and PCP diagnosed by responding only on Co-trimoxazole).

Infections involving lower respiratory tract (bronchitis and pneumonia) are more 25 folds in HIV patients than in other population, it is represent by up to 90 cases per 1,000 PLWH per year. In the pre-ART era, *P. aeruginosa* was a common cause of community acquired pneumonia in HIV cases. Also, bronchopulmonary infections by *P. aeruginosa* in HIV patients with advanced state have been described [11].

The only one PCP case in this study was unfitted for bronchoscopy and on Cotrimoxazole therapeutic test for three weeks and the patient showed good response while was not responding to non-specific antibiotics. This long course was comparable to *Benito et al., 2012 [11]* findings; HIV patients infected by PCP may have sub-acute symptoms and needs longer duration to control in relation to other immunocompromised patients.

There were four patients (8%) young intravenous drug users (IDUs) males presented by bilateral cavitory lesions consistent with blood born septic embolizations due to infective endocarditis (IE) as on echocardiography there were vegetations of variable sizes on right side of the heart tricuspid and right atrium without history of valvular heart disease.

One of those four infective endocarditis (IE) patients was complicated by empyema which was drained and the patient started ART with the recommended antibiotics and discharged after one month, another one had cured without complications, one missed from follow up after two weeks of improvement, and the fourth was not admitted and died within one week.

There were 2 (2.6 %) of our patients presented by lymphoma. HIV related lymphoma was representing a frequent complication in HIV patients before ART, and then the incidence has markedly dropped in developed countries while it represents an increasingly problem in developing one [12].

There were no unique manifestations that distinguished KS from other pathologic processes in the lungs and the coincidence of Kaposi and TB is predicted in advanced HIV in absence of treatment, the patient in this study was first presented by picture consistent with TB confirmed by therapeutic test then develops skin lesion one month later and pathologically diagnosed by skin biopsy.

Asthma and COPD were presented in 8 of cases (15%), this relative high incidence was comparable to *Drummond and Kirk 2014 [13]* findings in HIV patients; they concluded that in addition to accelerated decline in pulmonary functions (Forced vital capacity in first second decreased by about 55–75 mL/year) and reduced diffusing capacity that was seen in up to 50% of them, 16–20% of PLWH had asthma or COPD, and as progression in HIV state occurs there was consequently worsening in spirometry and diffusing capacity.

Whether the increased risk represents a biological mechanism mediated by the HIV virus or shows confounding by behaviors

associated with poor HIV treatment outcomes that lead to COPD development is unclear [9].

#### CONCLUSION

HIV patients with advanced immune suppression are vulnerable group for chest complications from acute bronchitis to malignancy.

#### REFERENCES

- 1- **Adler MW:** ABC of Aids: Development of the epidemic. *BMJ*. 2001; 322:1226.
- 2- **Mocroft A, Ledergerber B, Katlama C, A Forouzan, Z Shushtari, H Sajjadi, Yahya Salimi, et al.:** Decline in the AIDS and death rates in the EuroSIDA study: an observational study. *Lancet*. 2003; 362:22.
- 3- **Costiniuk CTI and Jenabian MA.:** The lungs as anatomical reservoirs of HIV infection. *Rev Med Virol*. 2014; 24(1), 35:54.
- 4- **Day CL, Mkhwanazi N, Reddy S, Mncube Z, Stok M, Toidi Adekambi, et al.:** Detection of polyfunctional Mycobacterium tuberculosis-specific T cells and association with viral load in HIV-1 infected persons. *J Infect Dis*. 2008; 197, 990:999.
- 5- **Tachado SD, Zhang J, Zhu J, Patel N and Koziel H.:** HIV impairs TNF alpha release in response to toll-like receptor 4 stimulation in human macrophages in vitro. *Am J Respir Cell Mol Biol*. 2005; 33, 610:621.
- 6- **Gordon SB, Molyneux ME, Boeree MJ, Mas Chaponda, S. Bertel Squire and Robert C.:** Opsonic phagocytosis of Streptococcus pneumonia by alveolar macrophages is not impaired in human immunodeficiency virus-infected Malawian adults. *J Infect Dis*. 2001; 184, 1345:1349.
- 7- **Grubb JR, Moorman AC, Baker RK, and Masur Henry:** The changing spectrum of pulmonary disease in patients with HIV infection on antiretroviral therapy. *AIDS*. 2006, 12, 1095:1107.
- 8- **Sigel K, Wisnivesky J, Shahrir S, B Sheldon T, Justice Amy, Kim Joon, et al.:** Findings in asymptomatic HIV-infected patients undergoing chest computed tomography testing: implications for lung cancer screening. *AIDS*. 2014; 287:1007–14.
- 9- **Madeddu G, Fois AG, Calia GM, S. Babudieri, V. Soddu, F. Becciu, et al.:** Chronic obstructive pulmonary disease: an emerging comorbidity in HIV-infected patients in the HAART era? *Infection* 2013; 41:347–53.
- 10- **Gokengin Deniz, Fardad Doroudi, Johnny Tohme and Navid Madani:** HIV/AIDS: trends in the Middle East and North Africa region. *International Journal of Infectious Diseases* 44 (2016) 66–73
- 11- **Benito N., A. Moreno, J.M. Miro and A. Torres:** Pulmonary infections in HIV-infected patients: an update in the 21st century. *Eur Respir J* 2012; 39: 730–745.
- 12- **Matthew Ulrickson, Oliver W. Press, and Corey Casper:** Epidemiology, Diagnosis, and Treatment of HIV-Associated Non-Hodgkin Lymphoma in Resource-Limited Settings. *Advances in Hematology* 2012, Article ID 932658, 7 pages.
- 13- **Drummond Bradley and Gregory D Kirk (2014):** HIV-associated obstructive lung diseases: insights and implications for the clinician. *Lancet Respir Med*. 2014; 2(7): 583–592